

The use of aesthetic flexible removable partial dentures (FRPD) has sky-rocketed over the last several years (Figure 1). Multiple advertisements can be found in every journal with laboratories promoting lower cost (compared to conventional partial dentures with cast frameworks), fast service, and better aesthetics than conventional metal-based removable partial dentures (RPD). In speaking with prosthodontists, I still get the feeling they believe that the use of FRPDs is somehow still not quite the right thing to do. Although, some are now openly admitting that these prostheses may, in fact, have their place, I think that many are still a bit unsure about exactly what that place is. This article will describe techniques needed to provide aesthetic FRPDs to your patients, and I will also share my opinions regarding these appliances and the need to embrace them as a viable treatment option.

RIGID METAL-BASED RPDS VERSUS FLEXIBLE RPDS

Part of the problem for some to accept FRPDs is that they don't just violate many of the "rules" of RPDs—they simply ignore them. And yet, despite this, they are still successful. There are no rest seats transmitting the axial load down the long axis of the tooth. There are no infra-bulge clasps and supra-bulge clasps (in the traditional sense), and the tissue does not seem to care that these devices are non-rigid. All these things violate the traditional concepts of classic metal-based (rigid) RPD design. And yet, there are a rapidly growing number of these appliances being delivered to patients every year, demonstrating that their popularity is springing from practicing dentists, and not from dental schools and/or leading prosthodontists.

There is little classic scientific research to support the use of FRPDs, and the constellation of articles and thought that surround traditional metal-clasped (rigid) RPDs does not yet exist for these devices. Interestingly, if one reads through enough articles beginning with clasp concepts originating in the "Dental Cosmos" of the early 1930s, it becomes clear that clasp design for metal-based RPDs is in truth very much a matter of opinion and conjecture. Even hard core "scientific" articles—like those based on stress studies using light refraction models (Do these truly reflect what is happening in bone and tissue?); or those based on various lab devices that show movement/flexure of arms/clasps under deformation (They may be great metallurgical studies, but are they directly and clinically applicable?); and the multitude of articles with drawing after drawing showing points of rotation, rest seat axial load, and so on—are accepted as stone-hard truth. If history shows us one thing, it is that facts can be manipulated to support any number of concepts, and that the general consensus on something may have some built-in errors. In other words, it can be quite difficult to separate fact from fiction.

OBSERVATIONS AND INDICATIONS

From the perspective of my personal clinical experience, the facts are simple: FRPDs (such as Valplast [Valplast International, Inc.]) work extremely well in some situations, and reasonably well in others. Although some periodontists have been quick to tell of some cases or situations where tissue stripping has occurred with the use of these appliances, I have not observed this condition in cases that I have done, nor in patients that I have seen who were treated by other dentists. In the small number of patients I have observed who have worn FRPDs for an extended period of time, I have not seen bone damage or resorption in the traditional pattern of posterior ridge resorption (saddle ridge) that is so common under chrome/acrylic saddles used on metal-based RPDs. Time and increased patient utilization may bring some of these issues forward, but for the moment they do not seem to be a problem. Present observations reveal that patient satisfaction with FRPDs is high, the equipment costs and technology to make them are low, and the aesthetics can also be outstanding when compared to conventional metal-based RPDs.

FRPDs are extremely useful as a provisional in lieu of restorative temporaries or a standard acrylic partial. While the cost is a little more, the higher patient satisfaction usually found with these, and the fact that they will not break, is worth any extra expense. No repairs are necessary, and no patients are at the door with a broken acrylic partial in hand.

FRPDs have also been used successfully as obturators in conjunction with maxillectomy procedures. The weight of the appliance (Valplast) is usually about one third that of the conventional obturator. In addition, the clasping and stability potentials can often far exceed that of a metal-based RPD used in the same fashion.

MATERIAL CONSIDERATIONS AND DESIGN CONCEPTS

When I first started encouraging others to try a FRPD (specifically Valplast), I found that several of my friends had tried it and had a somewhat discouraging experience. Rather than extolling its virtues, I was curious to know what problems they had experienced. Questioning exposed a basic flaw in their execution and design, in that they treated (whether intentionally or not) Valplast as some kind of idifferent acrylic. Our dental experiences are shaped by acrylic, specifically forms of methyl methacrylate. We often carry this "acrylic bias" with us into other areas without realizing it. FRPDs are not just some other form of methyl methacrylate, and attempting to treat it as such will result in a disappointing experience—guaranteed!

This is not the first time when new techniques and materials have arrived in the field of dentistry—change is in the air (not just from the fumes of a spilled monomer) and this is just one more that we have to face! So, the first and most important thing is to eliminate the "acrylic habit." This means that you will have to eliminate your traditional thoughts about how to grind and adjust this flexible material. It is not easily adjusted, especially if you attempt to do it with instruments and burs with which you are used to adjusting acrylic. The next thing you need to let go of is the "clasp habit." Flexible polynylon (Valplast) is not wrought wire or PGP wire to be soldered to a cast framework. It is also not cast round, cast tapered, "back to back," and is not just like any other metal clasp. Metal clasp rules apply to metal clasps, not to Valplast. The quickest way to end up with bad results is to confuse the 2, a mistake that far too many commercial laboratories are still making.

This translates to the basic concept: care and attention is needed to successfully design and utilize this material for a removable prosthesis.

MODELS, SURVEYING, AND TOOTH PREPARATION

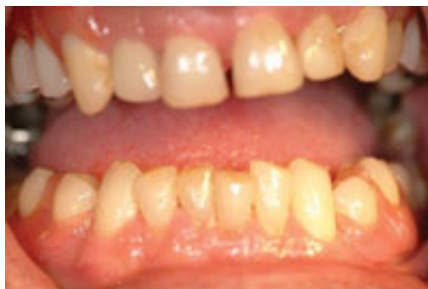

Figure 1. Aesthetic partials are possible with modern materials and thoughtful designs.

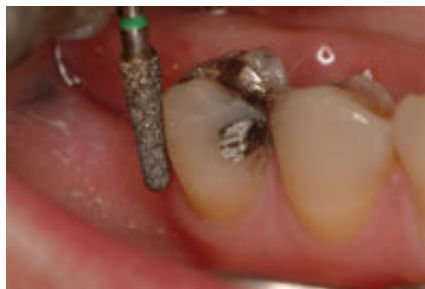

Figure 2. Light enameloplasty to create survey zone.

As in most things in dentistry, the FRPD begins with an accurate diagnostic model. An accurate opposing model is also essential since the occlusion will dictate the placement of components; and because success can only come through careful consideration and incorporation of the occlusion into the final design.

Survey the teeth on the stone model: level the plane of occlusion, stabilize the surveyor table, and run the carbon rod around the teeth. That's the survey line. It sounds dangerously traditional, but is now a new concept. Metal clasps were all about survey lines, being above them or being below them. This concept, although important, is different with flexible partials. Polynylon/Valplast likes a "survey zone," not a survey line. The survey line just indicates to you where you are going to take a fine-tapered diamond and do a little enameloplasty (Figure 2). Think of it as making a 2.0 mm guideplane that goes around the tooth. That survey zone, or circumferential guideplane, is the generator of the required stability and retention.

A LOOK AT CLASP DESIGNS

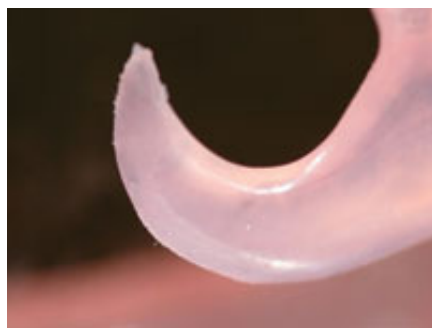

Figure 3. Bulk is not required for strength or retention.

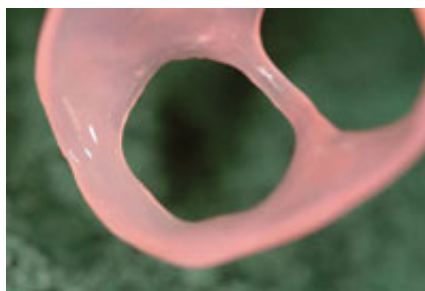

Figure 4. A circumferential clasp.

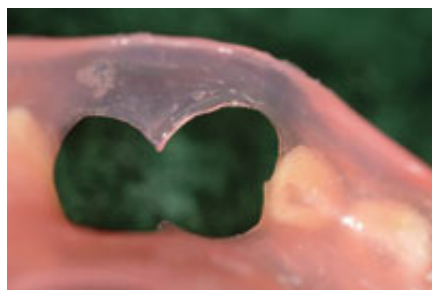


Figure 5. A 2-tooth continuous clasp. **Figure 6.** Circumferential clasp for a mesially-tipped distal molar.

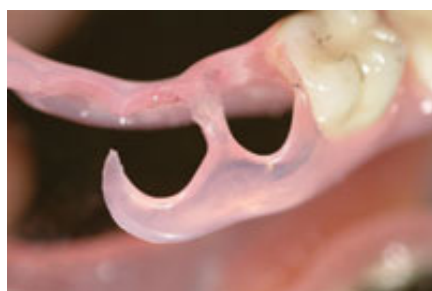
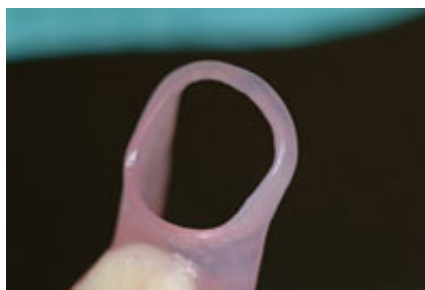
Figure 7. A combination clasp.

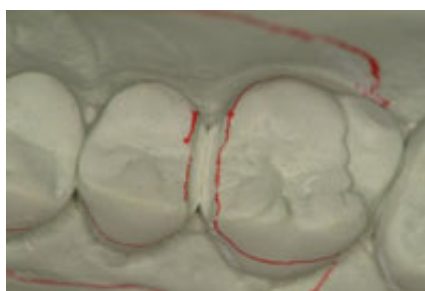


Figure 8. Preparation to allow for crossing the occlusal table.

Let's first consider the design of the "standard" or "main" clasp. If you look at any FRPD advertisement you will see the basic "main clasp" (Figure 3). This is certainly a useful clasp, but its design is often far too large and bulky. Tooth preparation to improve the contact zone is essential for increased retention and stability. These do not need to cover large amounts of tooth structure. A few millimeters of tooth contact and a few millimeters of tissue contact are all that is necessary for retention and stability. More is not better!

The circumferential clasp (Figure 4) is just that. It goes totally around a free-standing tooth. It can also engage all available surfaces of multiple teeth (Figure 5), in which case it may be referred to as a "continuous circumferential clasp." This is an ideal clasp for a free-standing, mesially-tipped distal abutment (Figure 6). What makes this clasp so unbelievably retentive is the prepared survey zone.

The combination clasp (Figure 7) is, in fact, a combination of the circumferential clasp and the conventional main clasp. Its key ingredient is a component that crosses the occlusal table. This component also acts as a "rest seat" and although it may or may not transfer load to the axial root of the tooth, it certainly does provide stability and strength to the FRPD by linking the palatal (or lingual) components to the buccal. This basic engineering concept of mutual reinforcement cannot be

overlooked or discarded. This can be accomplished through a prepared slot (Figure 7), if occlusion or restorations do not permit; or through a wide embrasure space that may be enlarged with a diamond (Figure 8). Valplast does not have to be thick and bulky, however, it does need a reasonable amount of material for strength. Therefore, it must be reinforced by components that link the palatal/lingual with the buccal.

TROUBLESHOOTING: CLASP DESIGNS TO AVOID

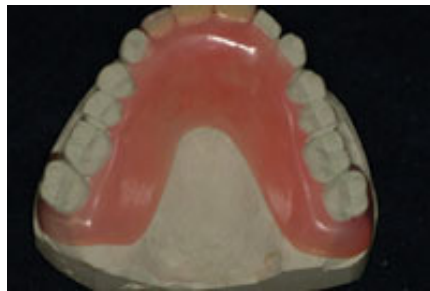

Figure 9. The "reach around" clasp design should be avoided.

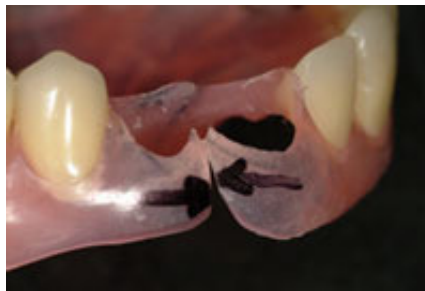

Figure 10. Separated clasps that lose strength and function.

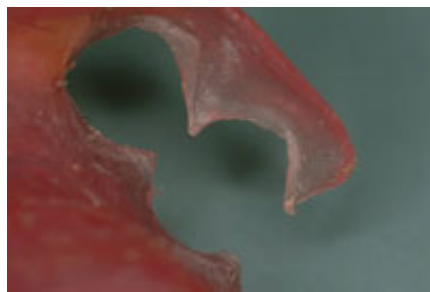


Figure 11. A hopeless 2-tooth clasp that will hinge open, providing no strength or retention.

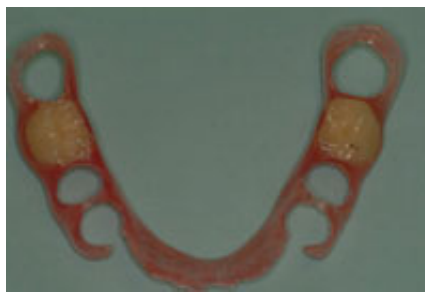

Figure 12. A well-designed flexible removable partial denture with 2 circumferential clasps and 2 combination clasps.

The "reach-around clasp" is almost the single worst design concept (Figure 9). It has to be waxed thick for adequate strength, and as a result, it becomes bulky and uncomfortable. I recently received such a clasp design from a laboratory where the prosthetic technician did not understand the concept of survey area, the circumferential clasp, or combination clasp design. The patient was not impressed by the size, look, or feel of what they provided for us. This type of clasp is usually done by a dental technician that simply does not understand the concept of crossing the occlusal table for strength, rigidity, and retention.

The "separated" clasps (Figure 10) are also a waste of strength and retention. These are clasps from a laboratory in which the prosthetic technician still thought clasps were made of metal and had to be separate. This technician sacrificed all the strength of the circumferential clasp and gained nothing in exchange.

The prize for simply the worst design and execution is the 2-tooth clasp (Figure 11). Clinically it will always be a failure. This is because the physics will force the unsupported end to hinge away from the tooth surface when it is seated. It will have absolutely no function, no retention, and be of no use. The only thing possible here was to remove it.

CONCLUSION

The use of FRPDs is growing. Patient success is high since these appliances can be extremely aesthetic. One must remember that careful attention must be paid to the basic concepts of diagnosis and design, and a different approach to clasp design is essential (Figure 12).

I certainly do not believe that (FRPDs) are the answer to everything. However, they represent a great stride forward as an excellent prosthetic choice available for our patients. When appropriate, their use should be considered by dental health professionals as a viable treatment option.